

Performance Evaluation of Ru-106 Plaque for eye cancer Treatment:

Subject: Re: Ru-106 plaque

From: "Mahesh Shanmugam" <maheshshanmugam@gmail.com>

Date: Tue, July 14, 2020 4:24 am

To: cpk@barc.gov.in

"Nathiya" <nathiya_phy@yahoo.co.in>

“Dear Sir,
Greetings!

Thank you for giving us one of the first Ru-106 plaques for evaluation. We had used it to treat a patient with conjunctival lymphoma and I am glad to say that the lesion has regressed well 6 months post treatment. I am herewith sending the pre and post treatment photographs. Nathiya can send you the treatment parameters if you so require.

Look forward to using the future versions of the plaque .

warm regards and thanks

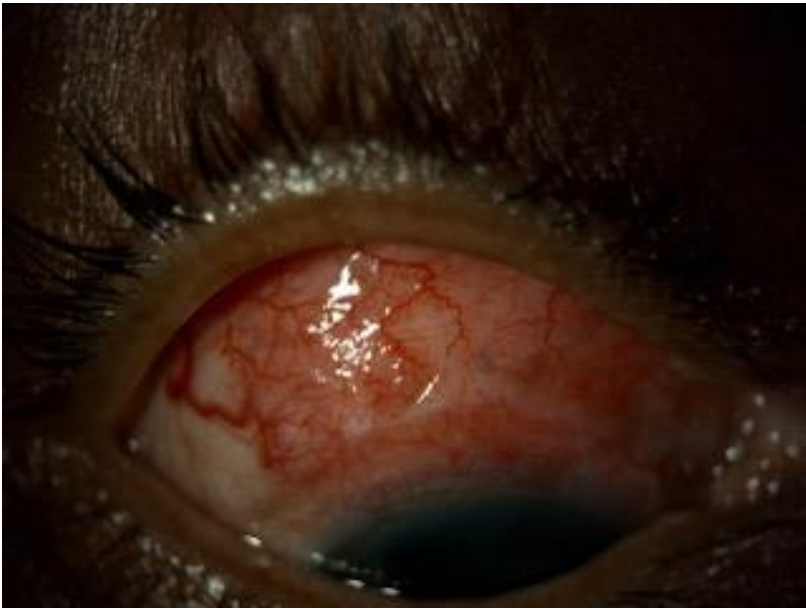
Mahesh”

Email Received from: Dr.P.Mahesh Shanmugam, MBBS, DO, FRCSEd, PhD, FAICO Head,
Vitreoretinal and Oncology Service, Sankara Eye Hospital,
Kundalahalli gate, Airport, Varthur Road, Bangalore.

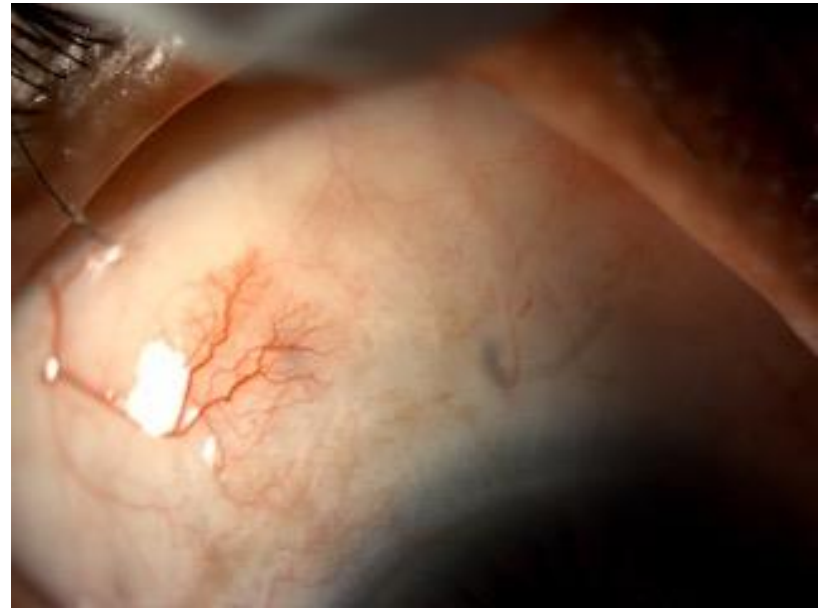
Ph: 080-28542727 / 28 / 29

Performance Evaluation of Ru-106 Plaque for eye cancer Treatment:

Courtesy: Dr.P.Mahesh Shanmugam, Sankara Eye Hospital



Pre-treatment Image of eye showing signs of conjunctival lymphoma



Post-treatment Image indicating near elimination of cancer